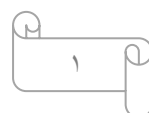
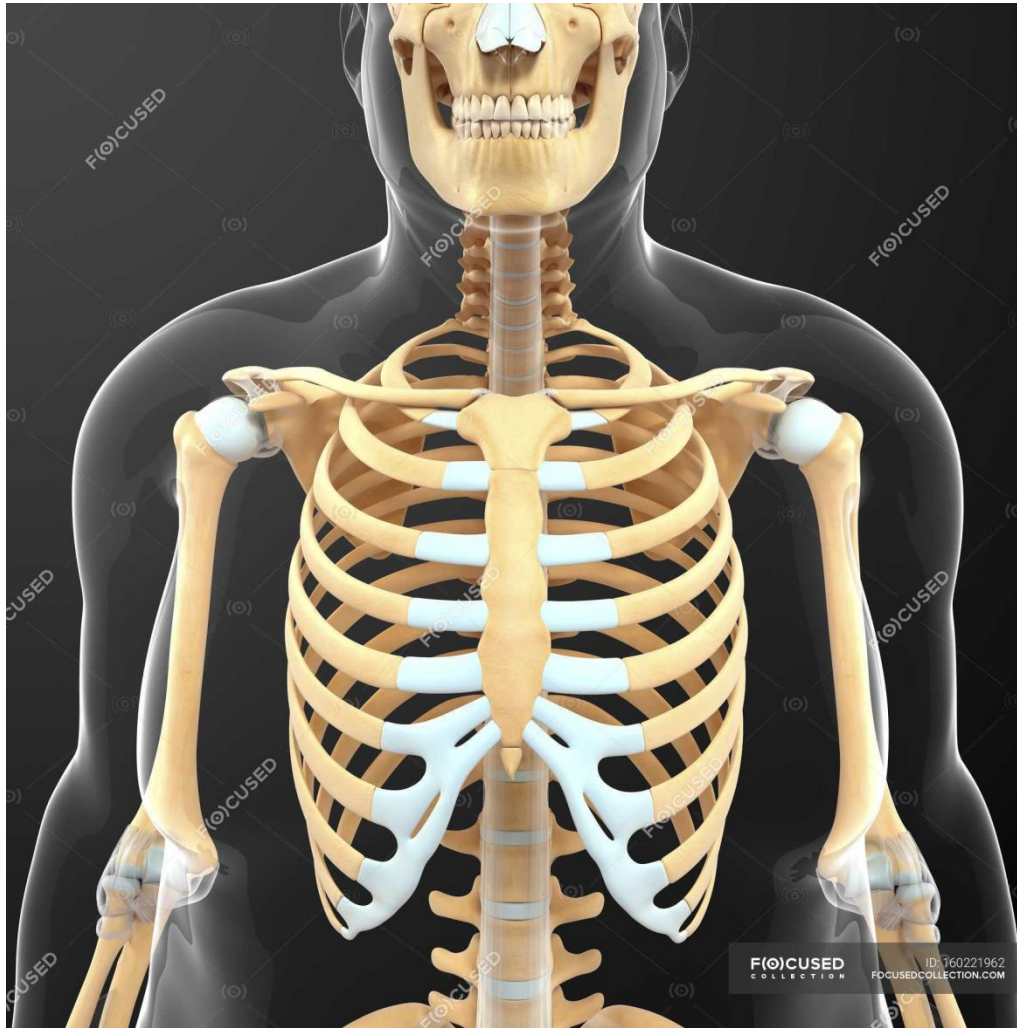

BONES OF THE UPPER LIMB



The Bones of UL are:

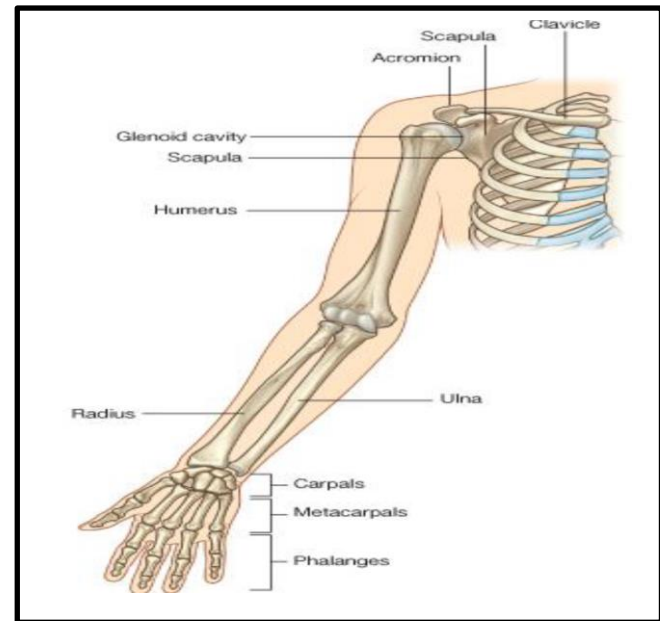
Pectoral Girdle.

Arm : Humerus.

Forearm : Radius & Ulna.

Wrist : Carpal bones

Hand: Metacarpals & Phalanges

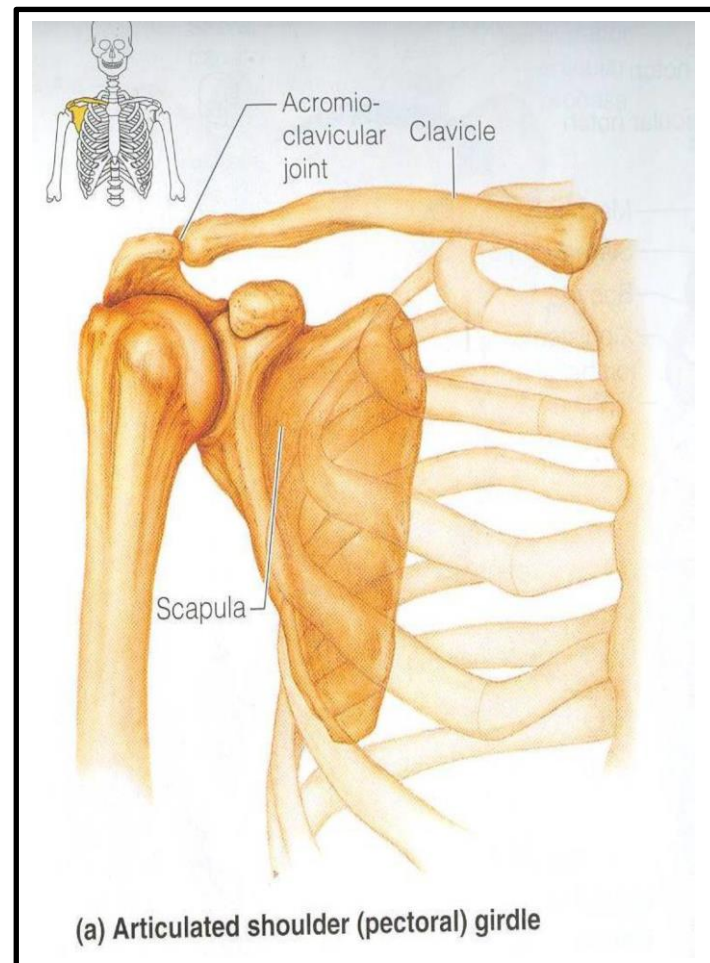


Pectoral Girdle

*Formed of Two Bones:

*Clavicle (anteriorly) and Scapula (posteriorly).

*It is very light and allows the upper limb to have exceptionally free movement.



Clavicle

It is a long bone with no medullary cavity.

It has the appearance of an elongated letter Capital (S) lying on one side.

It has Two Ends:

Medial (Sternal): enlarged & triangular.

Lateral (Acromial) : flattened.

Body (shaft):

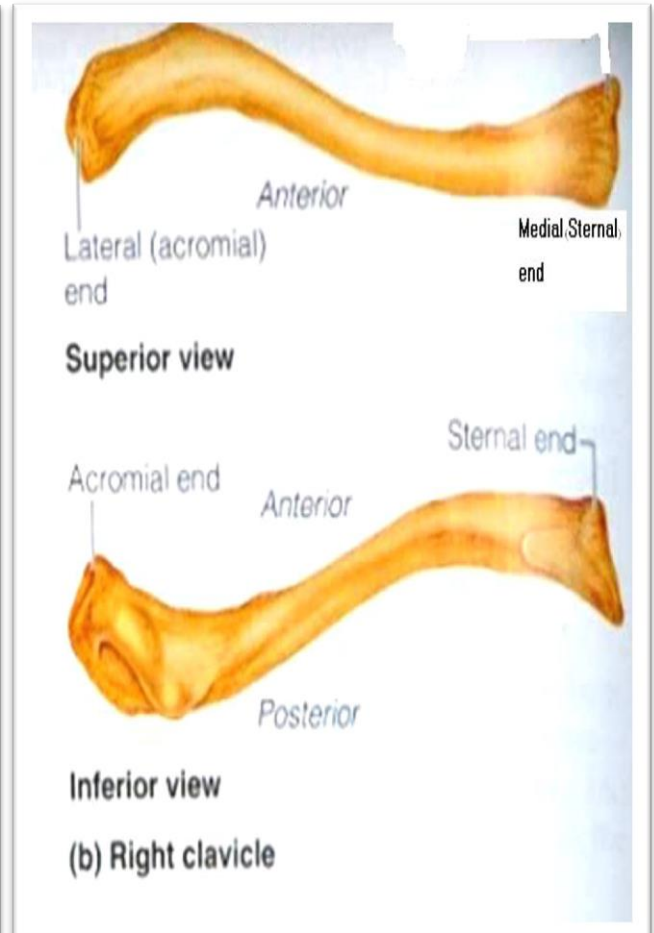
*Its medial 2/3 is convex forward.

*Its lateral 1/3 is concave forward.

*Surfaces:

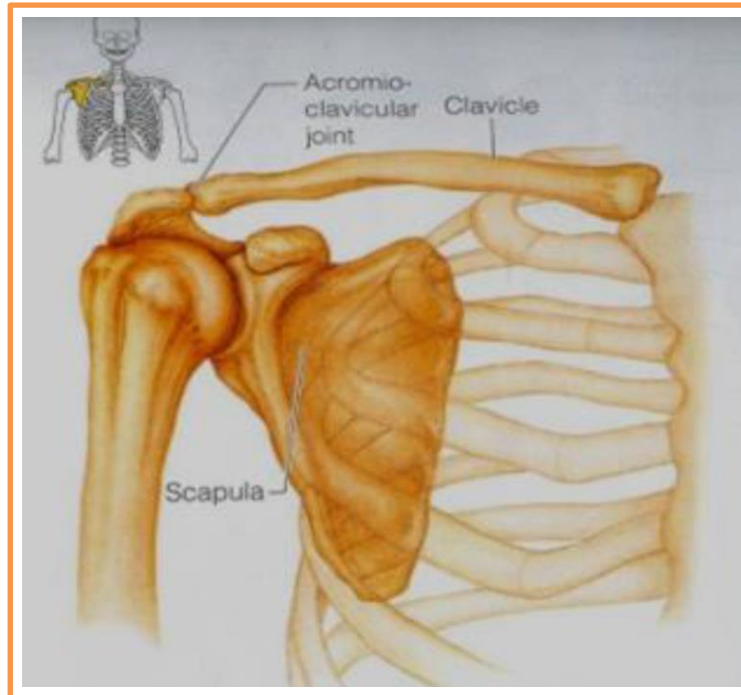
*Superior : smooth as it lies just deep to the skin.

*Inferior: rough because strong ligaments bind it to the strib.



Articulations of Clavicle

- *Medially with the manubrium at the Sternoclavicular joint .
- *Laterally with the Scapula at the Acromioclavicular joint
- *Inferiorly with the rib at the Costoclavicular Joint



Scapula (Shoulder Blade)

It is a triangular Flat bone.

*Extends between the 2nd _ 7th ribs.

*It has :

*Three Processes:

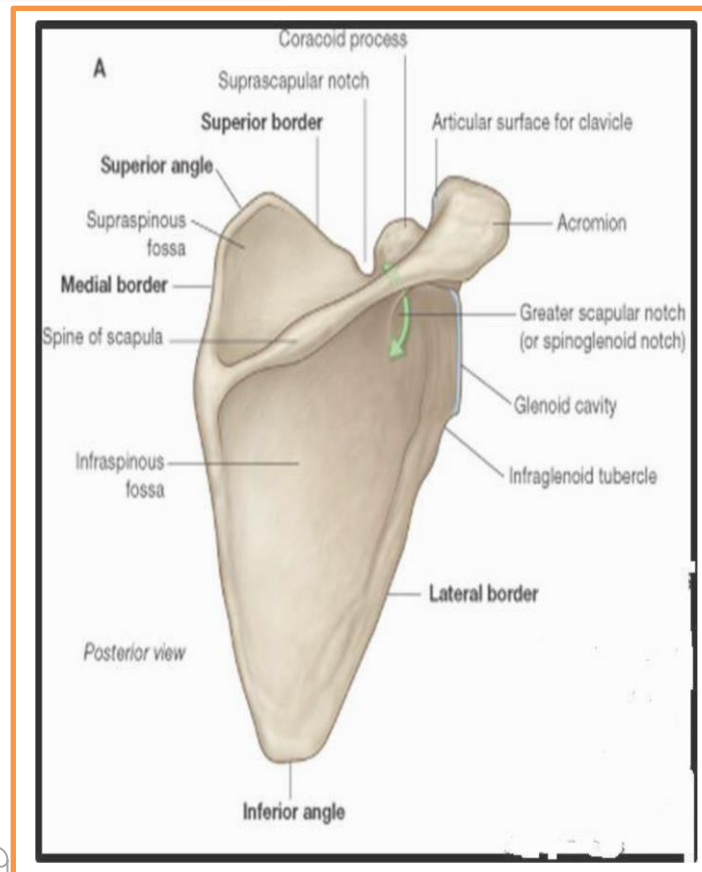
*(1)Spine: a thick projecting ridge of bone that continues laterally.

*(2) Acromion: forms the subcutaneous point of the shoulder.

*(3) Coracoid: a beak like process.

*It resembles in size, shape and direction a bent finger pointing to the shoulder.

*Three Borders: Superior, Medial (Vertebral) & Lateral (Axillary) (the thickest) part of the bone, it terminates at the lateral angle .



*Three Angles :

*Superior.

*Lateral(forms the Glenoidcavity) : a shallow concave oval fossa that receives the head of the humerus.

*Inferior.

*Two Surfaces:

1.Convex Posterior : divided by the spine of the scapula into the

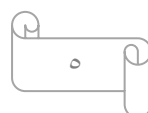
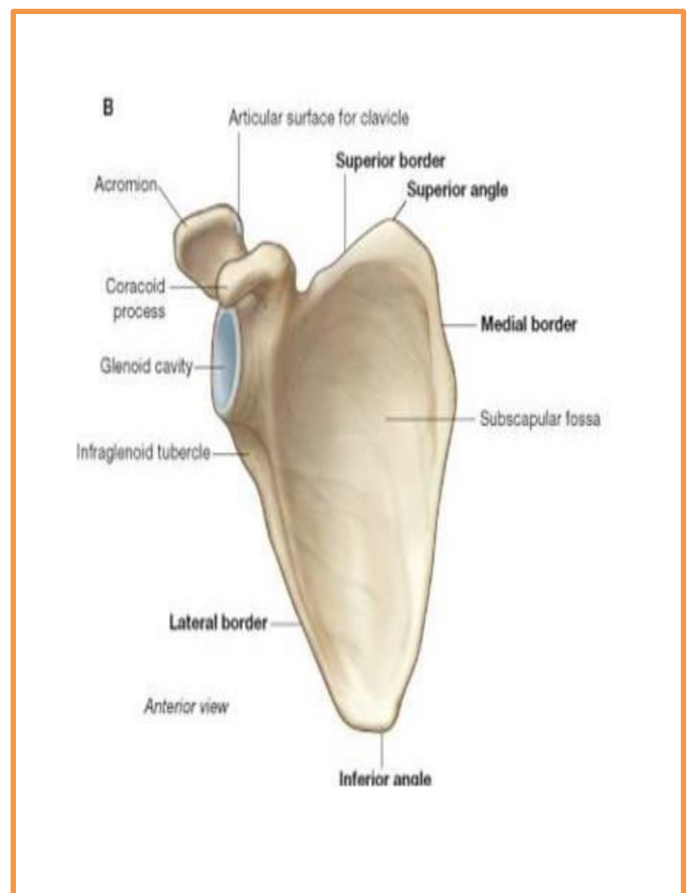
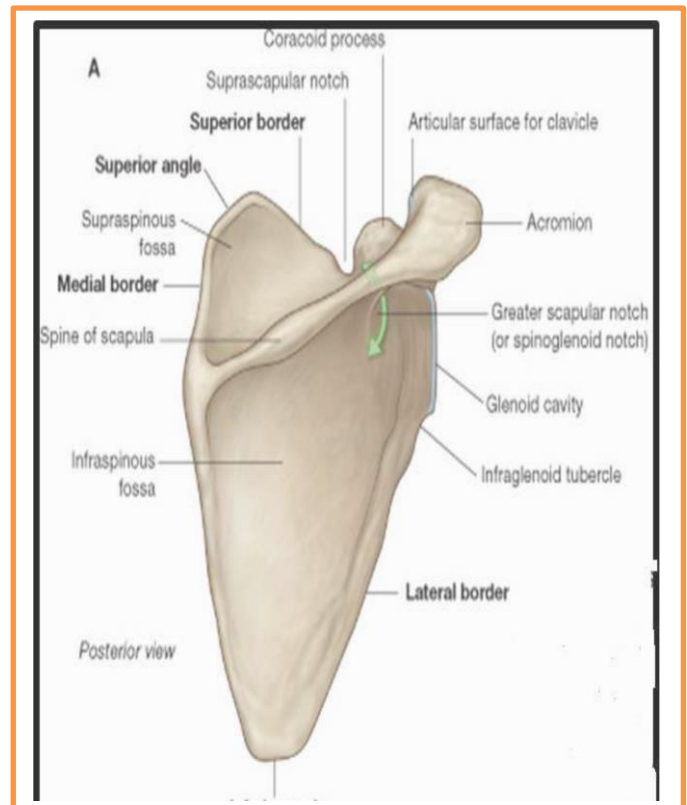
Smaller Supraspinous Fossa

*(above the spine) and the

*larger Infraspinous Fossa

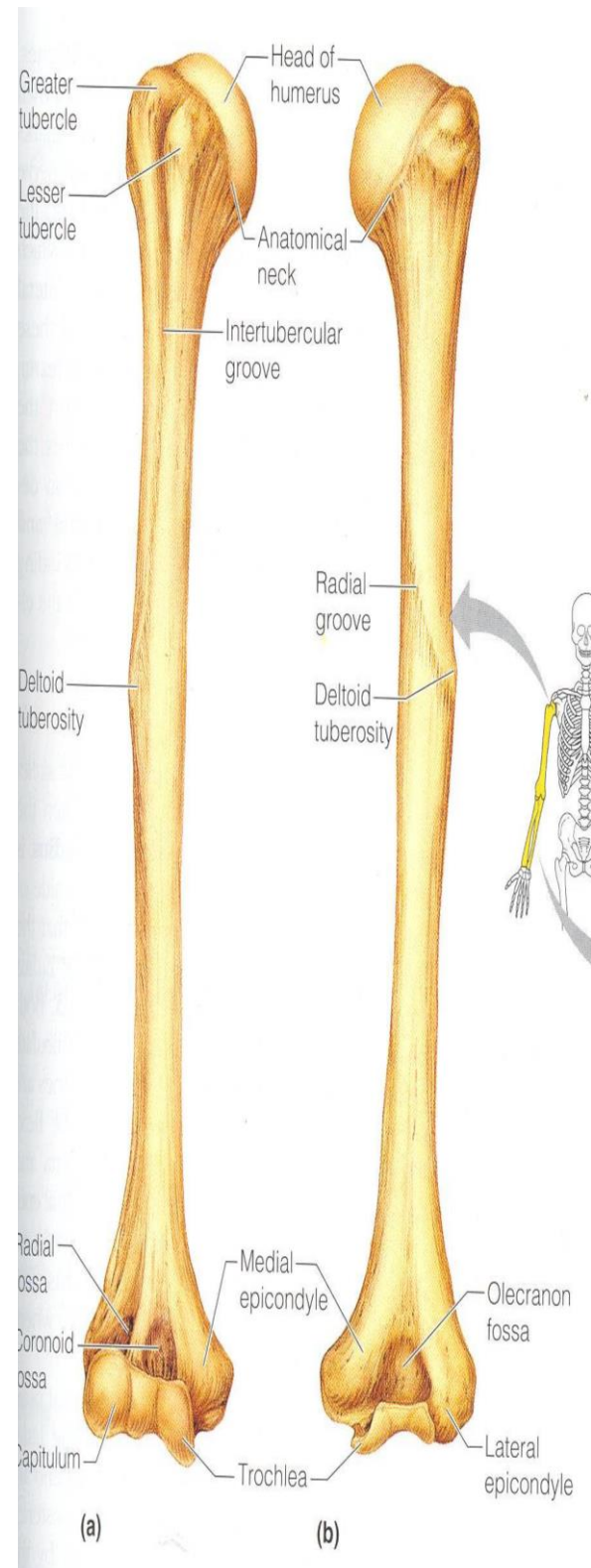
*(below the spine).

2.Concave Anterior (Costal): it forms the large Subscapular Fossa.



Humerus

- *A typical Long bone.
- *It is the largest bone in the UL
- *Proximal End :
- *Head, Neck, Greater & Lesser Tubercles.
- *Head:Smooth
- *it forms 1/3 of a sphere, it articulates with the glenoid cavity of the scapula.
- *Greater tubercle: at the lateral margin of the humerus.
- *Lesser tubercle: projects anteriorly.
- *The two tubercles are separated by
- *Intertubercular Groove.
- *Anatomical neck: formed by a groove separating the head from the tubercles



***Shaft (Body):**

***Has two prominent features:**

1. Deltoid tuberosity:

A rough elevation laterally for the attachment of deltoid muscle.

2. Spiral (Radial) groove:

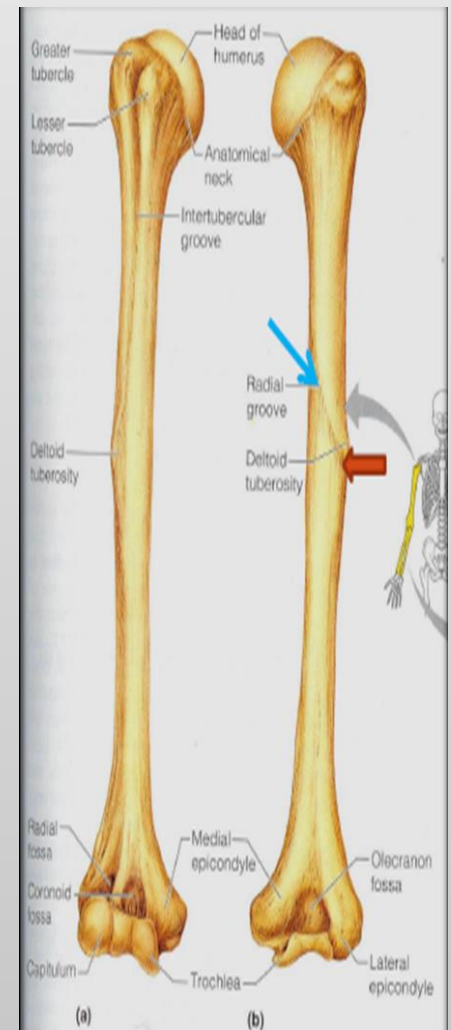
Runs obliquely down the posterior aspect of the shaft.

It lodges the important radial nerve & vessels.

***Distal End:**

Widens as the sharp medial and lateral supracondylar ridges and end in the Medial (can be felt) and Lateral Epicondyles.

They provide muscular attachment.



Structures at Distal end:

*Anteriorly:

Trochlea:(medial) for articulation with the ulna

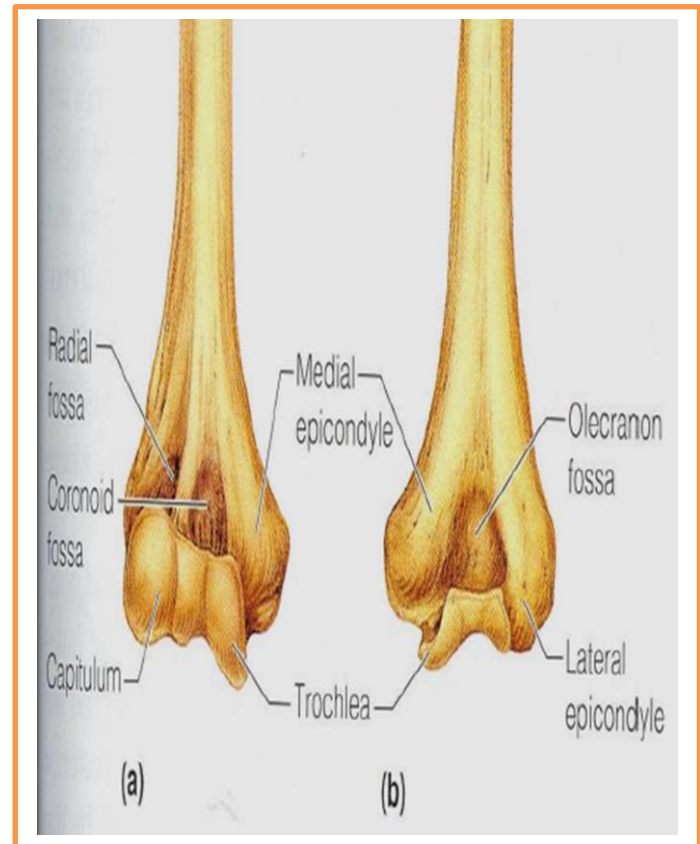
Capitulum:(lateral) for articulation with the radius.

***Coronoid fossa** :above the trochlea.

***Radial fossa**:above the capitulum.

Posteriorly:

Olecranon fossa :above the trochlea.



Ulna

It is the stabilizing bone of the forearm.

It is the medial & longer of the two bones of the forearm.

Proximal End

1. Olecranon Process :

projects proximally from the posterior aspect (forms the prominence of the elbow).

2. Coronoid Process :

projects anteriorly.

3. Tuberosity of Ulna:

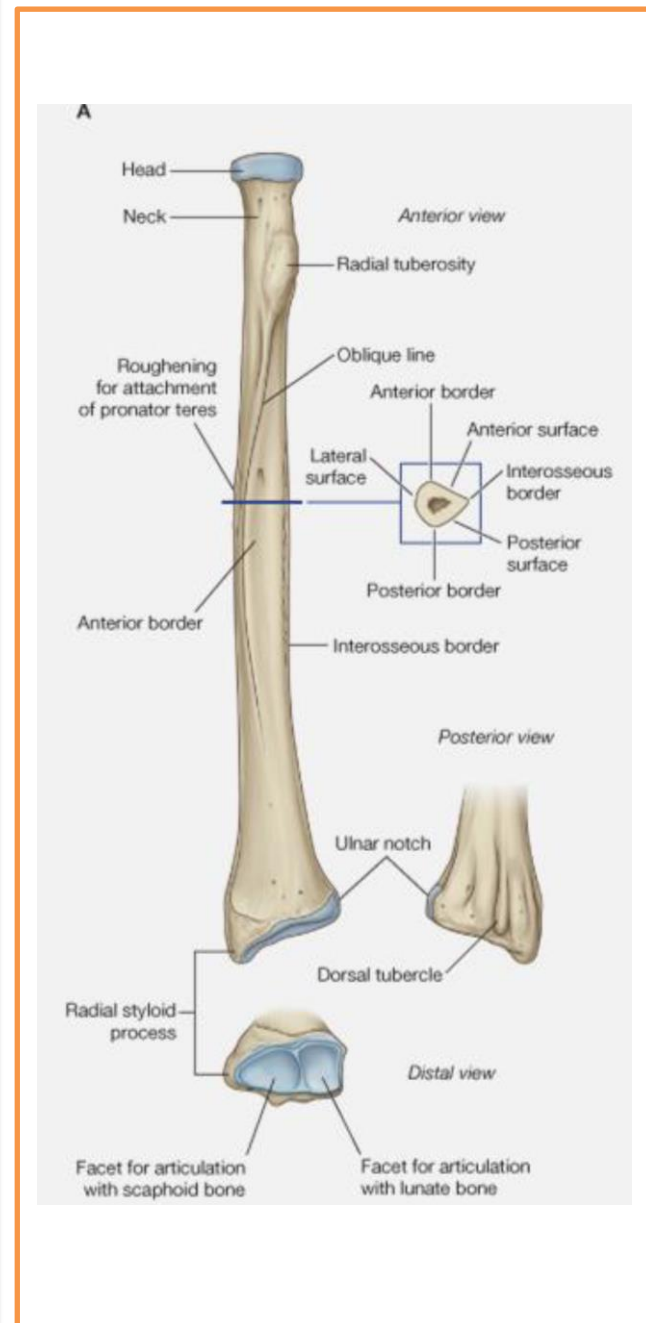
inferior to coronoid process.

4. Trochlear Notch:

articulates with trochlea of humerus.

5. Radial Notch :

a smooth rounded concavity lateral to coronoid process.



Shaft:

*Thick & cylindrical superiorly but diminishes in diameter inferiorly

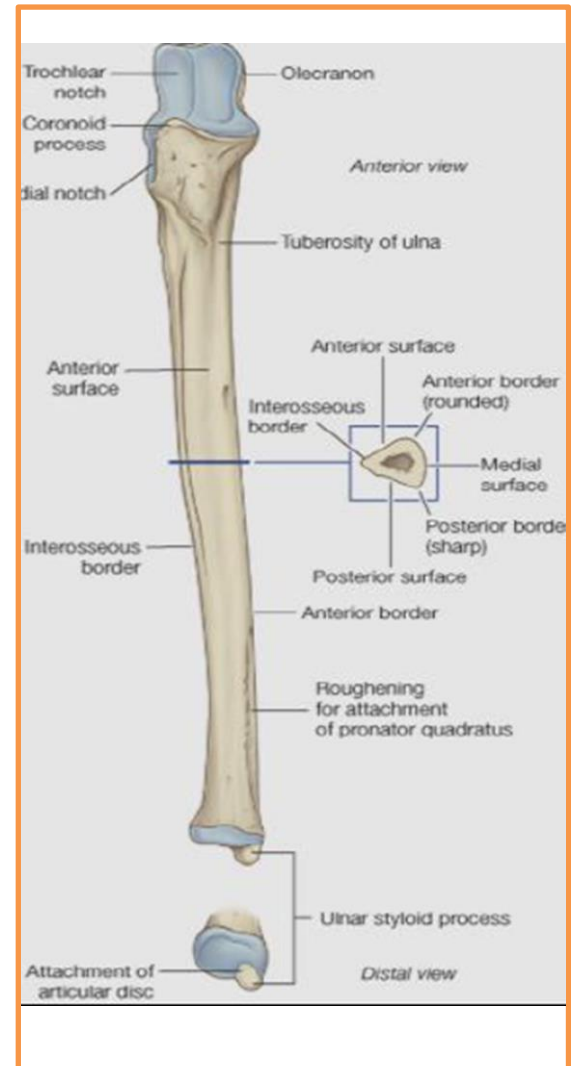
*It has Three Surfaces (Anterior, Medial & Posterior).

*Sharp Lateral Interosseous border.

*Distal End: Small rounded

1. Head:lies distally at the wrist. .

2. Styloid process:Medial.



Radius

It is the shorter and lateral of the two forearm bones.

Proximal End:

1. Head: small & circular

Its upper surface is concave for articulation with the Capitulum.

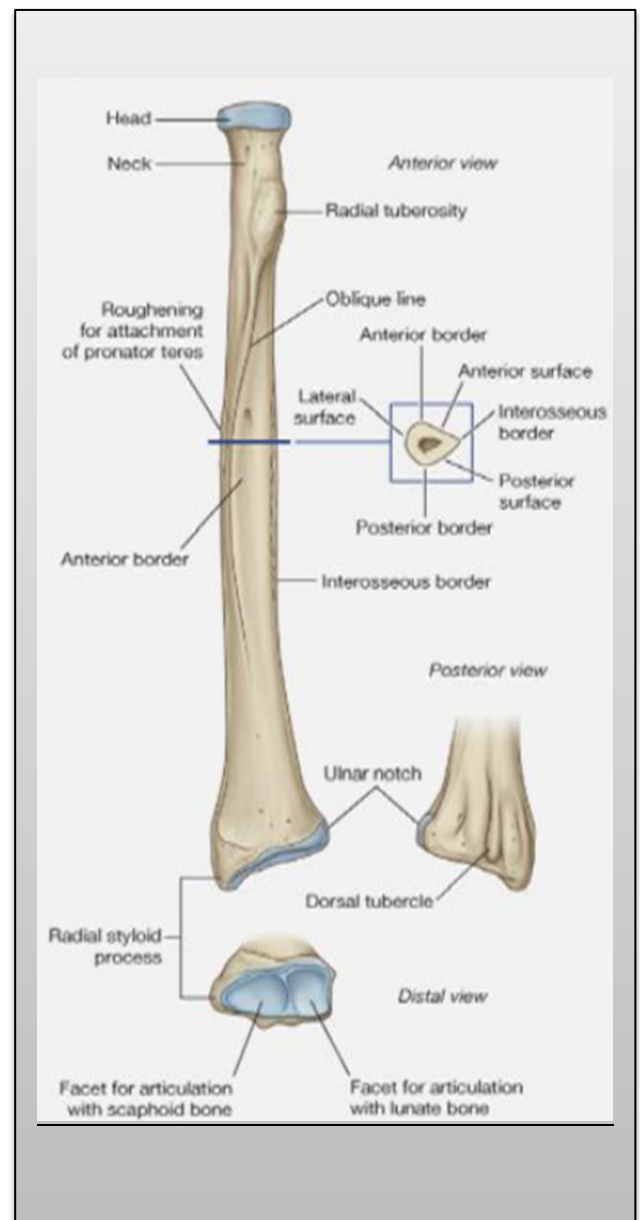
2. Neck.

3. Radial (Bicipital) Tuberosity: medially directed and separates the proximal end from the body.

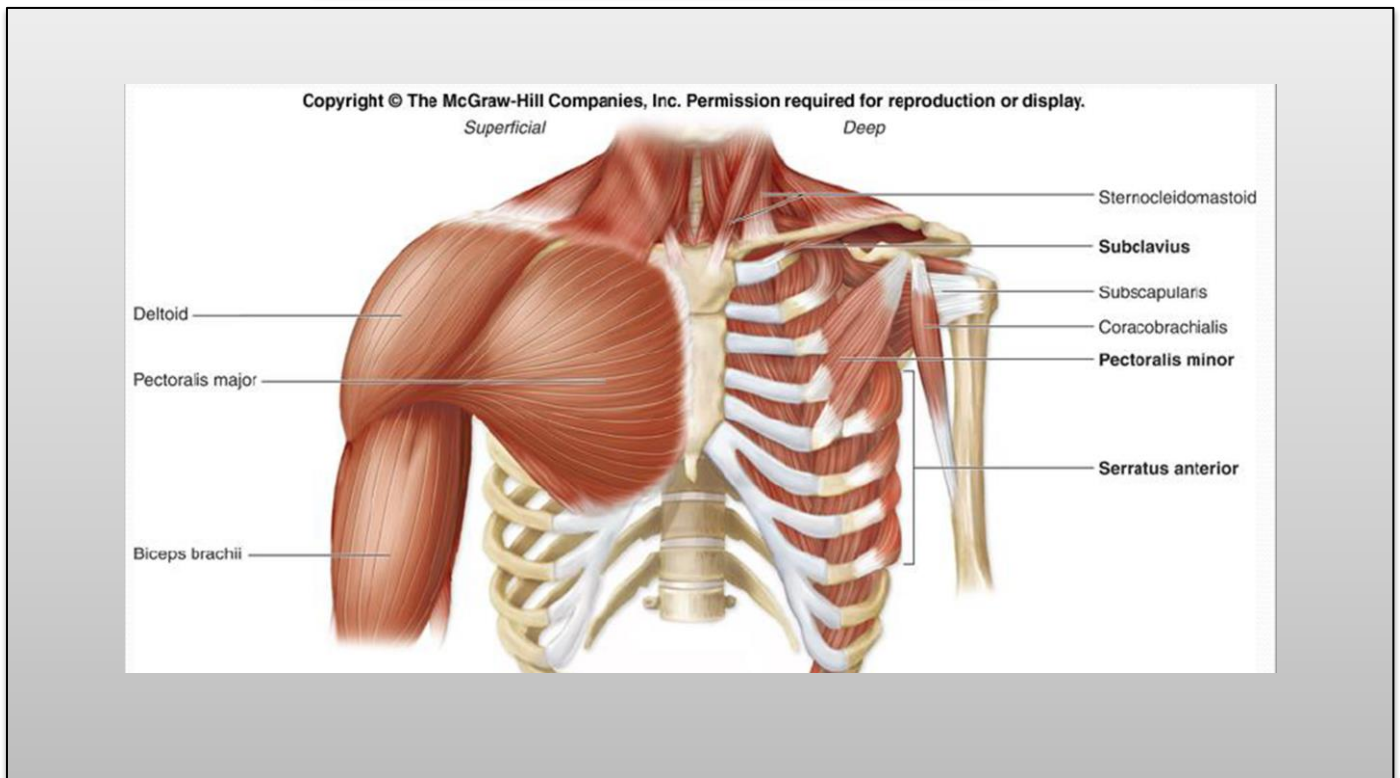
Shaft:

Has a lateral convexity.

It gradually enlarges as it passes



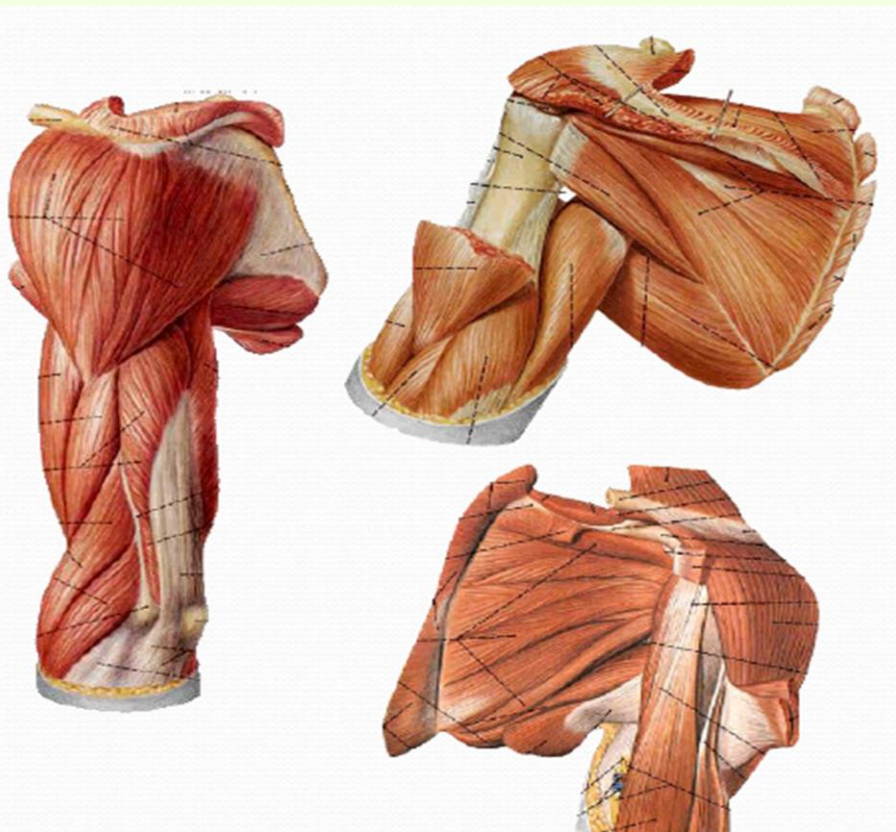
The upper limb muscles



The Muscles of Upper Limb

Muscles of shoulder

- 1-Deltoid
- 2-Supraspinatus
- 3-Infraspinatus
- 4-Teres minor
- 5-Teres major
- 6-Subscapularis



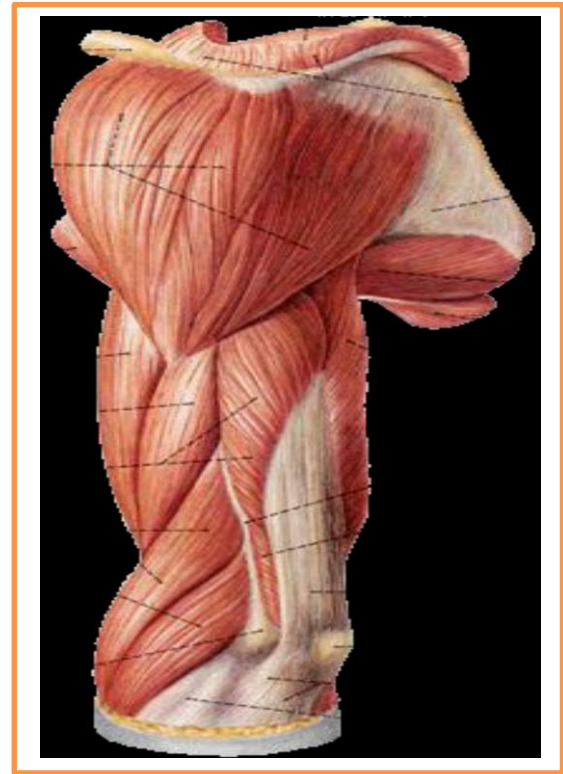
Major muscles of shoulder

Deltoid

***Origin:** lateral third of clavicle, acromion, and spine of scapula

***Insertion:** deltoid tuberosity of humerus

***Action:** flexion and extension, medial and lateral rotation of arm



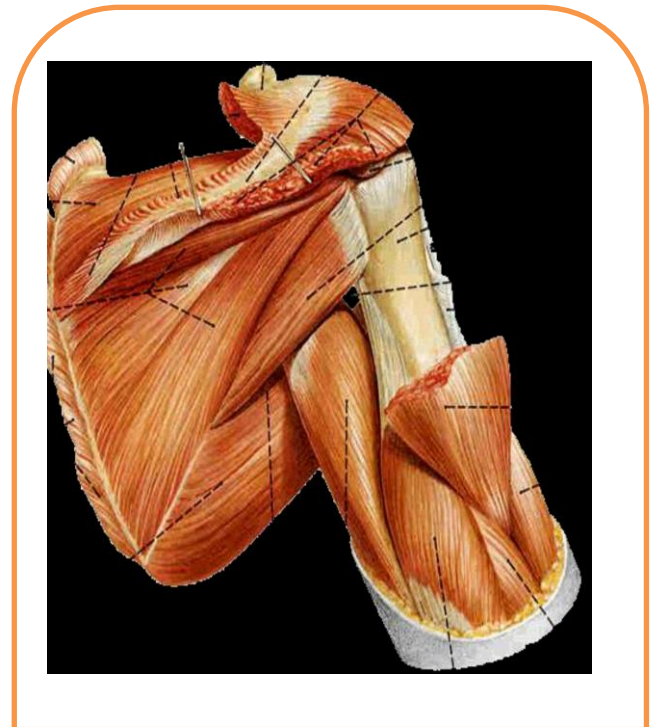
Major muscles of shoulder

Teres major

***Origin:** dorsal surface of inferior angle of scapula

***Insertion:** crest of lesser tubercle of humerus

***Action:** medially rotates and adducts arm



Arm and Forearm Muscles That Move the Elbow Joint/Forearm

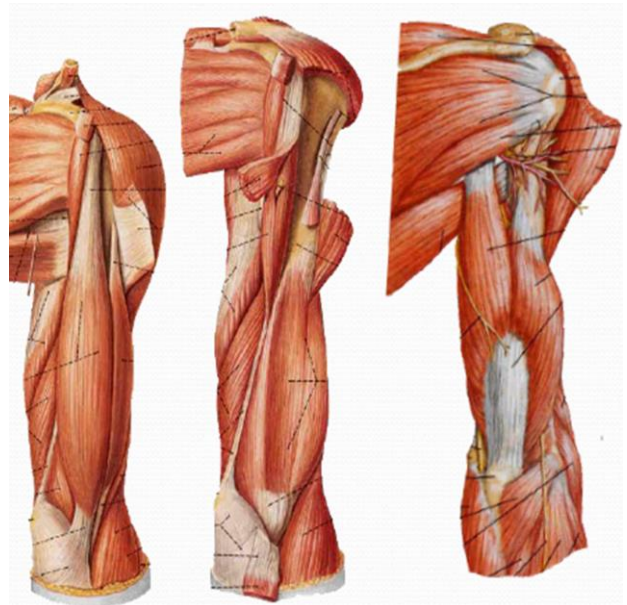
- 1-Anterior (flexor) compartment
- 2-Posterior (extensor) compartment
- 3-Anterior compartment
- 4-primarily contains elbow flexors
- 5-Posterior compartment contains elbow extensors
- 6-the principal flexors
- 7-biceps brachii, brachialis, and brachioradialis
- 8-muscles that extend the elbow joint
- 9-triceps brachii and anconeus.

Anterior group

- 1-Biceps brachii
- 2-Coraco brachialis
- 3-Brachialis

Posterior group

- 1-triceps brachii
- 2-anconeus



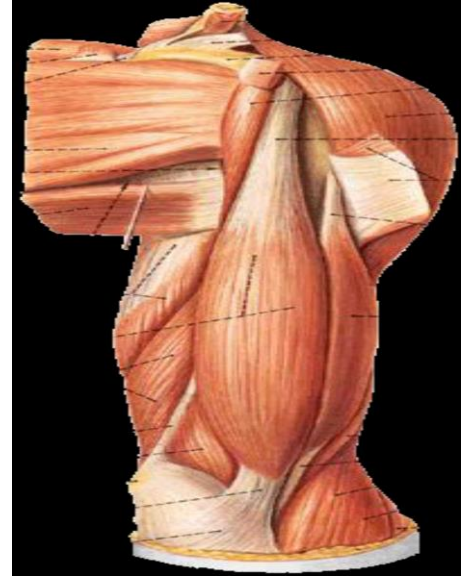
Muscles of arm

Biceps brachii

***Origin:** long head, supraglenoid tubercle; short head, coracoid process

***Insertion:** radial tuberosity

***Action:** supinator of forearm, flexor of elbow joint, weak flexor of shoulder joint



Muscles of arm

Triceps brachii

***Origin:**

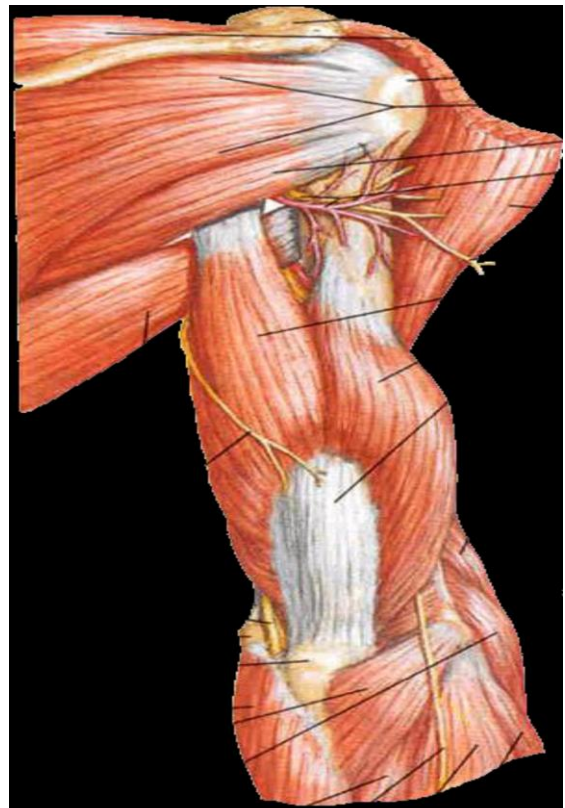
long head, infraglenoid tubercle

lateral head, above groove for radial nerve

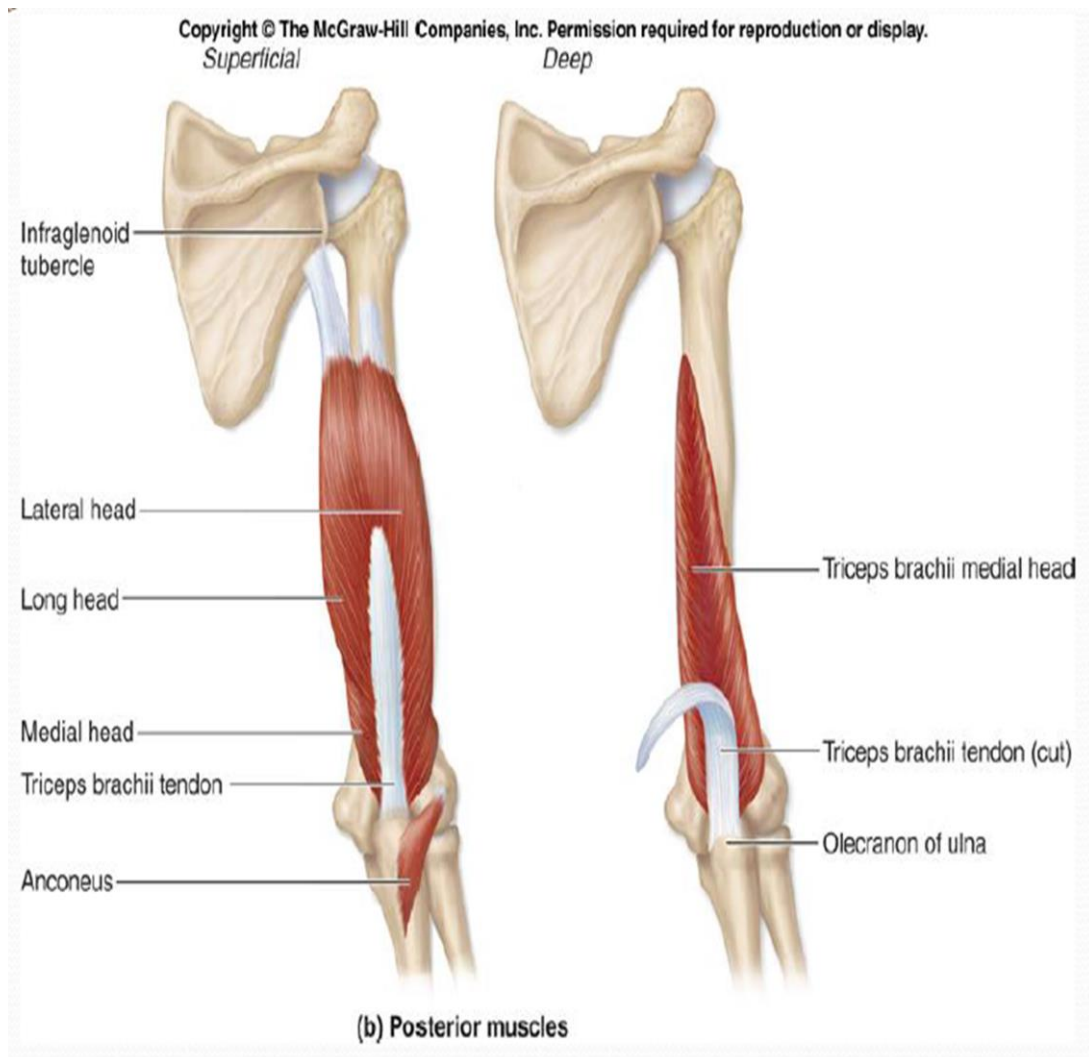
medial head, below groove for radial nerve

***Insertion:** olecranon of ulna

***Action:** extends elbow joint, long head extends and adducts shoulder joint



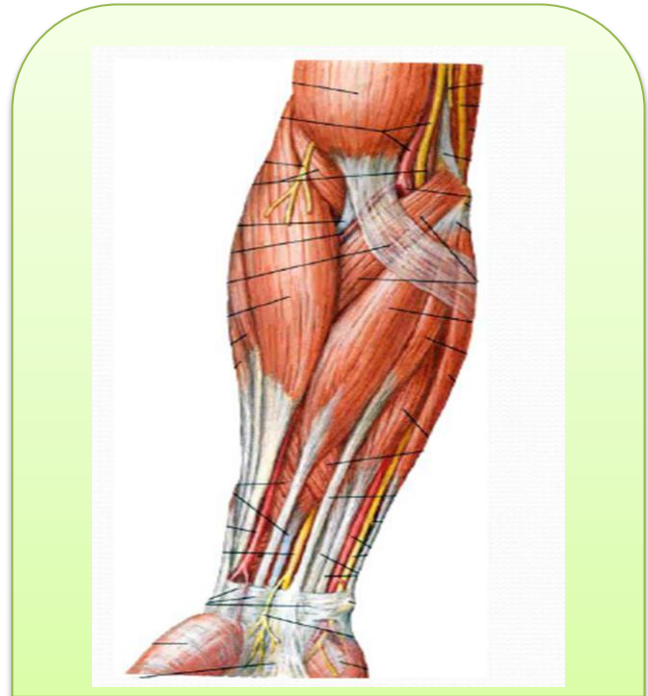
Triceps brachii



Muscles of forearm

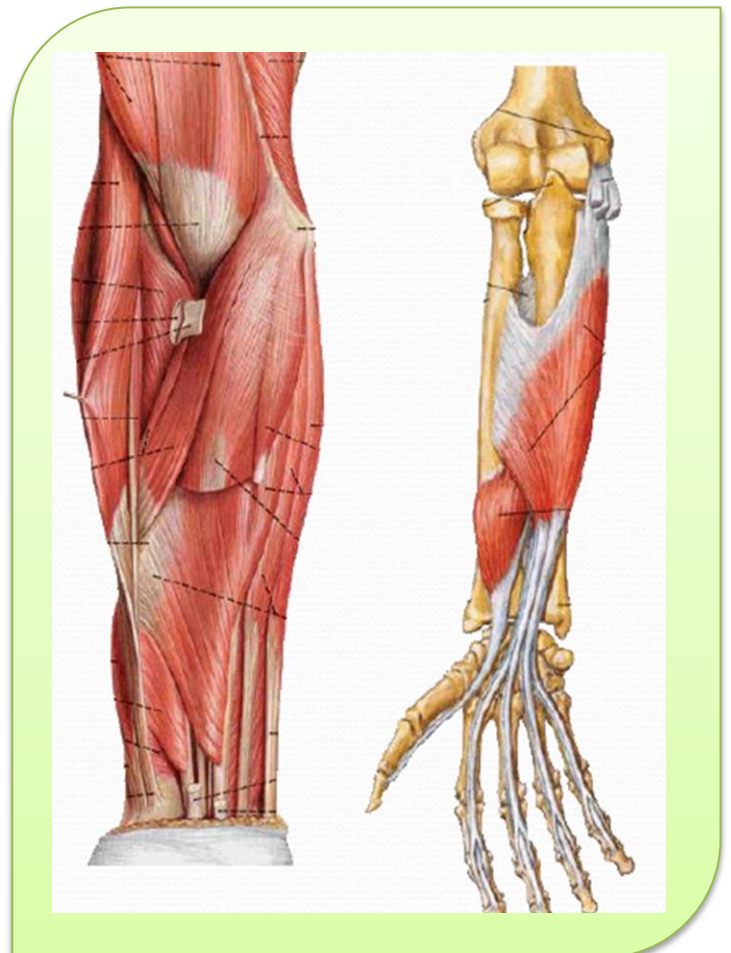
Superficial layer

- 1-Pronator teres
- 2-Flexor carpi radialis
- 3-Palmaris longus
- 4-Flexor carpi ulnaris



Second layer

Flexor digitorum superficialis



Third layer

1-Flexor digitorum profundus

2-Flexor pollicis longus

Fourth layer

Pronator quadratus

Action: flex radiocarpal joint
and fingers, pronate forearm

